

Making You Smile NYS  
36 E 36<sup>th</sup> St. 1D, New York, NY 10016  
646 484 0197  
[care@makingyousmile.nyc](mailto:care@makingyousmile.nyc)  
makingyousmile.nyc

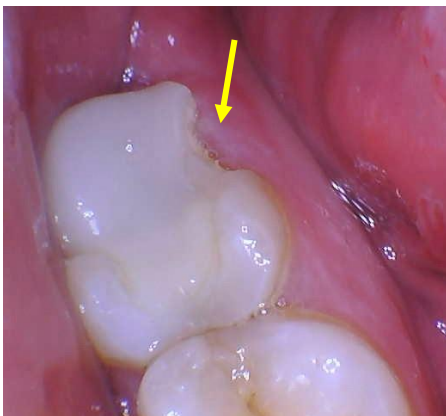


DEAR JACK,

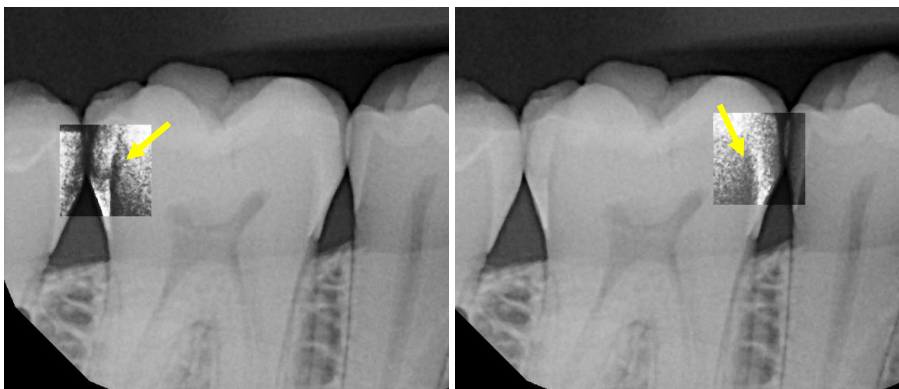Thank you so much for choosing our office for your dental care. Below you can find a summary of our first visit findings and discussion.

I did a comprehensive dental evaluation. My main findings are:

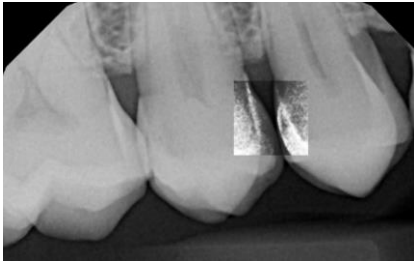
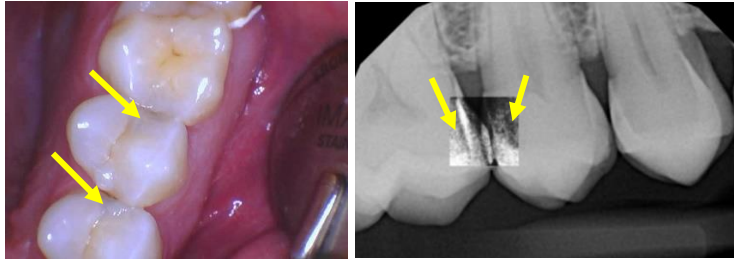
1. Your main complaint, the fractured lower right second molar #31.



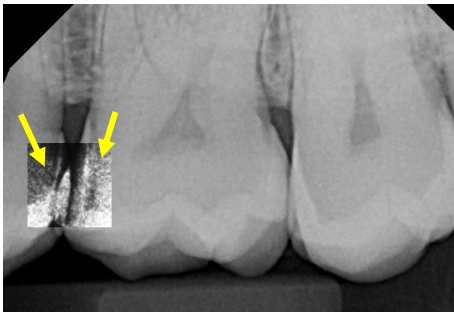
2. Caries (cavity, decay) on the tooth next to the fractured one, on both sides (mesial and distal) #30.



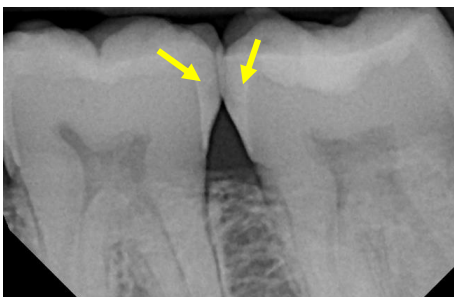3. Caries (cavities, decay) on your upper right first molar #3 (mesial) and premolars #4 (mesial and distal) +5 (distal).



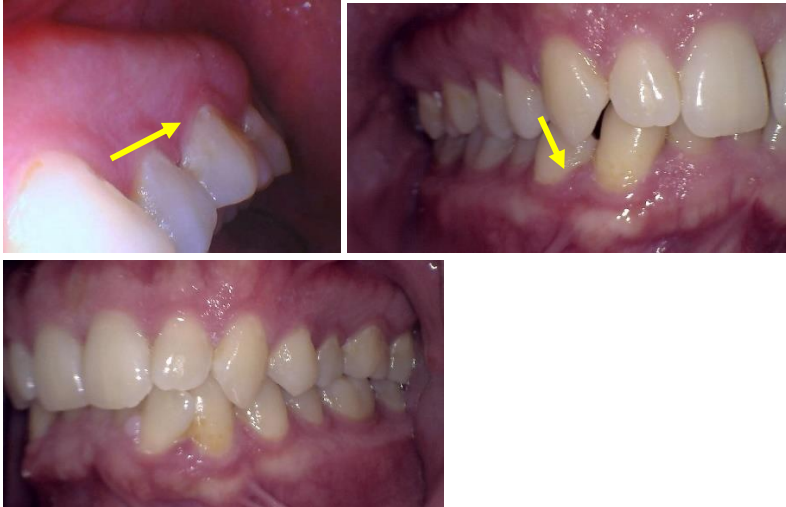4. Caries (cavities, decay) on your upper left first molar #14 (mesial) and premolar #13 (distal).



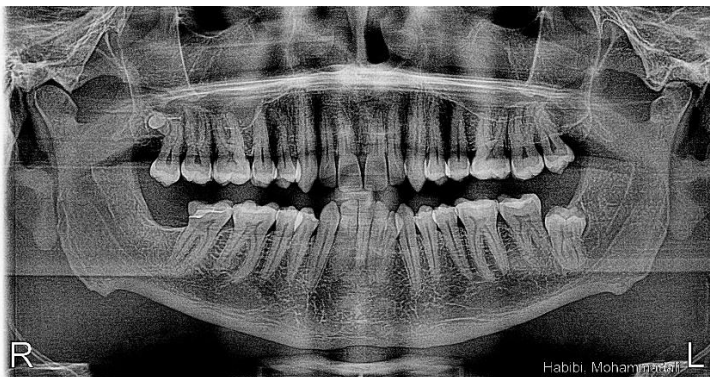
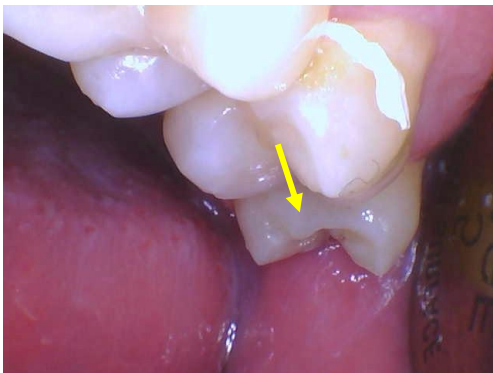
5. Incipient caries lesions limited to the enamel (outermost dense tooth layer) on multiple teeth.



6. Generalized mild gingivitis with plaque accumulation.

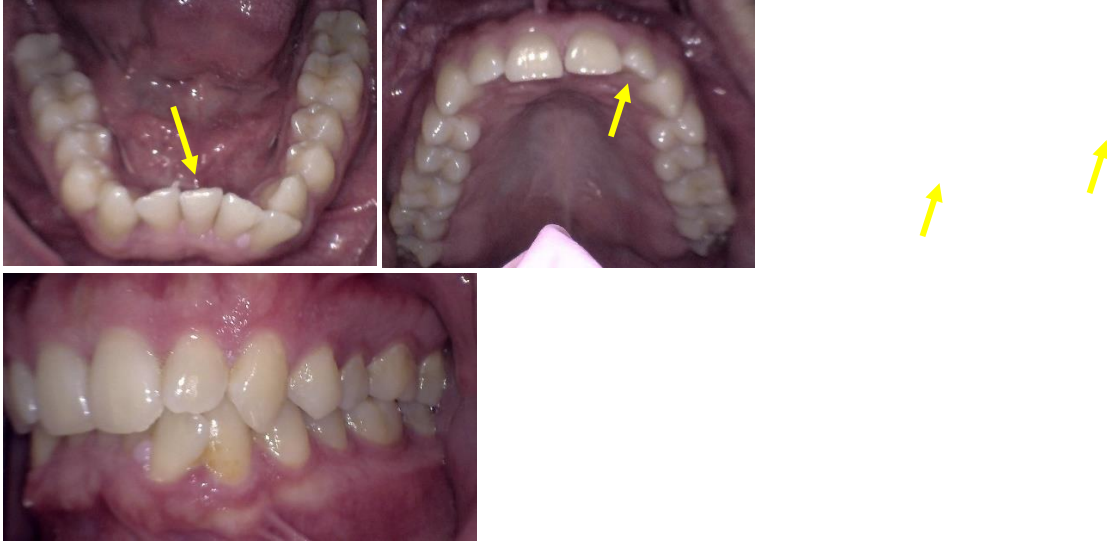

7. Super-erupted upper wisdom teeth due to the absence of opposing functional wisdom teeth on the lower and a possible supra-numerary wisdom tooth on the upper right.



8. Caries Risk Assessment (risk for future cavities) is high (range: low-moderate-high) due to points 2,3,4,5; more than 3 teeth with cavities.

9. Periodontal Risk Assessment (risk for future bone and gum disease) is low (range: low-moderate-high) due to absence of bone loss.
10. Misaligned teeth with crowding and super-eruption of the lower anterior and localized cross bite.



Recommended treatment:

- a. Dental cleaning to resolve the gingivitis point 6 and maintain periodontal health point 9.
- b. A crown on the lower right fractured tooth #31 and a tooth-colored composite filling on the tooth next to it #30, points 1 and 2.
- c. Tooth colored composite filling on the teeth with caries #3, 4, 5, 13, and 14, points 3 and 4.
- d. Extraction of the upper erupted wisdom teeth and an evaluation of the lower left wisdom tooth and supra-numerary wisdom by an oral surgeon (not urgent) point 7.
- e. Option to align the teeth and resolve crowding to address point 10. This will be done with clear aligners from Invisalign and will take 1 year +/- 6 months. Please let me know if you would like to discuss it further.

Completed treatment:

- Comprehensive exam, x-rays, and pictures.
- Presented an estimate for a, b, c, above.

Preventive care plan, will be discussed with you in details at your cleaning appointment, points 5 and 8:

- In office dental cleaning every 4 months with fluoride application to prevent future caries, re-mineralize and stop the progression of caries of the incipient lesions point 5.
- Home care (see video on our website landing page at [makingyousmile.nyc](http://makingyousmile.nyc)):
  - Nighttime:
    - First: **Floss**
    - **Rinse for 30 seconds with prescription mouthwash**: spit and do not rinse your mouth, eat or drink (every night of the first week of the month for 12 months).
    - Then: **Brush with prescription toothpaste**: light pressure and vibration at 45-degree angle for 2 minutes, spit the toothpaste, do not rinse your mouth, eat or drink (go straight to bed).
  - Morning time
    - **Brush with prescription toothpaste**: light pressure and vibration at 45-degree angle for 2 minutes, spit the toothpaste and do not rinse.

Please let me know if you have any questions. Again, thank you for your trust.

Best regards,

Ziad

Ziad Jalbout DDS DICOI

Clinical Associate Professor  
Department of Cariology and Comprehensive Dentistry 2016-2019

Department of Periodontology and Implant Dentistry 2003-2016  
New York University College of Dentistry